

## Images in Endoscopy

# Transcervical Embryoscopy: Images of First-Trimester Missed Abortion

Lucía T. Abdala, MD\*, Jesús A. Ruiz, MD, and Humberto Espinosa, MD

*From the Department of Minimally Invasive Surgery, Clínica Bautista, Barranquilla and Medifertil, Bogotá, Colombia.*

Transcervical embryoscopy is a hysteroscopy performed before obstetric curettage in cases of first-trimester missed abortion. It allows clear visualization of the demised embryo “in uterus,” adding useful information for the diagnosis of the cause of pregnancy failure [1].

The procedure is performed with the patient under general anesthesia and in the dorsolithotomy position, before obstetric curettage in patients with ultrasonographic diagnosis of fetal demise during the first trimester of pregnancy [2]. With a 5-mm 30-degree angle rigid hysteroscope and 0.9% normal saline solution, with pressures between 50 to 100 mm Hg, the vagina, cervical canal, uterus, tubal ostium, parietal decidua, and chorion are visualized. The opening of

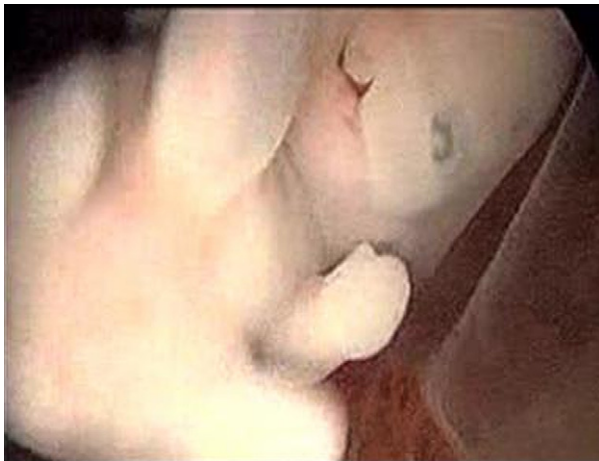

Fig. 1. Seven-week embryo with cleft lip.

The authors have no commercial, proprietary, or financial interest in the products or companies described in this article.

Corresponding author: Lucía Abdala, MD, Department of Minimally Invasive Surgery, Clínica Bautista, Barranquilla, Colombia. E-mail: [lucyabdala@hotmail.com](mailto:lucyabdala@hotmail.com)

Submitted January 25, 2009. Accepted for publication February 20, 2009. Available at [www.sciencedirect.com](http://www.sciencedirect.com) and [www.jmig.org](http://www.jmig.org)

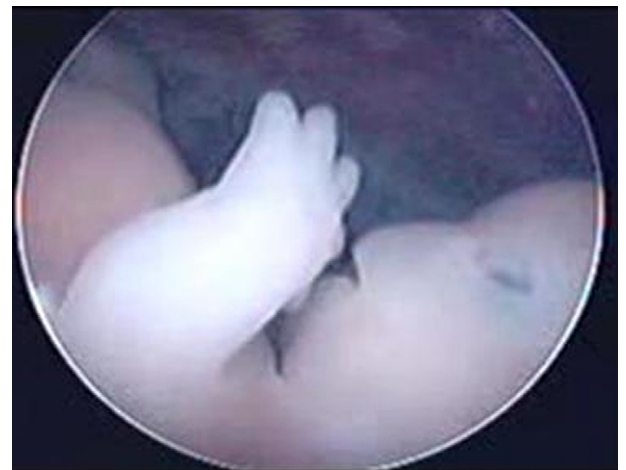

Fig. 2. Eight-week embryo with absence of nasal bone more common in trisomy 21.

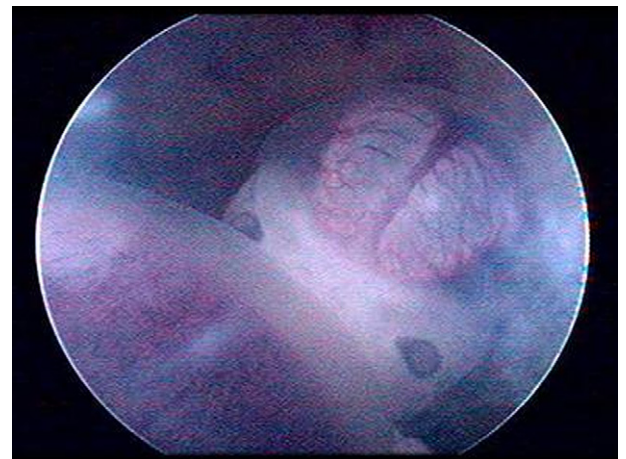


Fig. 3. Ascites in a 9-week embryo with hydrops fetalis.

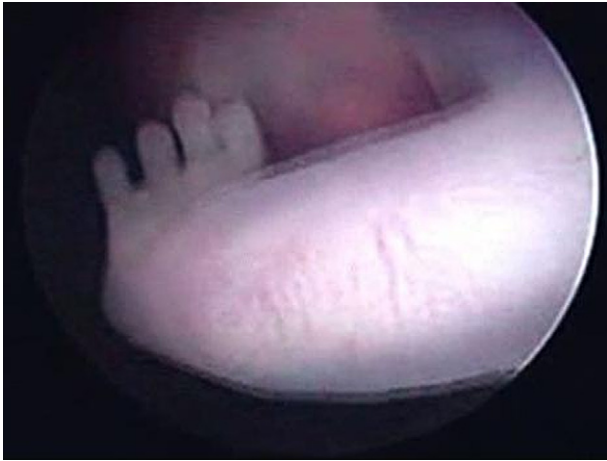

Fig. 4. Limb malformation in a 10-week embryo with syndactyly.

the chorion and amnion is performed with microscissors. A complete visualization of the embryo is recorded and analyzed. Cytogenetic analysis is taken directly from the demised embryo to avoid tissue contamination [3].

The diagnosis of morphologic abnormalities visualized through transcervical embryoscopy (Figs. 1-4) is correlated with the results of the karyotype analysis. This valuable information is important for genetic counseling, especially in patients with recurrent pregnancy loss [4].

## References

1. Cullen MT, Reece A, Whetham JD, Hobbins JC. Embryoscopy: description and utility of a new technique. *Am J Obstet Gynecol.* 1990;162:82–86.
2. Philipp T, Kalousek DK. Generalized abnormal embryonic development in missed abortion: embryoscopic and cytogenetic findings. *Am J Med Genet.* 2002;111:43–47.
3. Philipp T, Philipp K, Reiner A, Beer F, Kalousek DK. Embryoscopic and cytogenetic analysis of 223 missed abortions: factors involved in the pathogenesis of developmental defects of early failed pregnancies. *Hum Reprod.* 2003;28:1724–1732.
4. Ruiz J, Corredor E, García C, Madero J. Embrioscopia en aborto retenido. *Rev Colombiana Obstet Ginecol.* 2006;57:207–210.